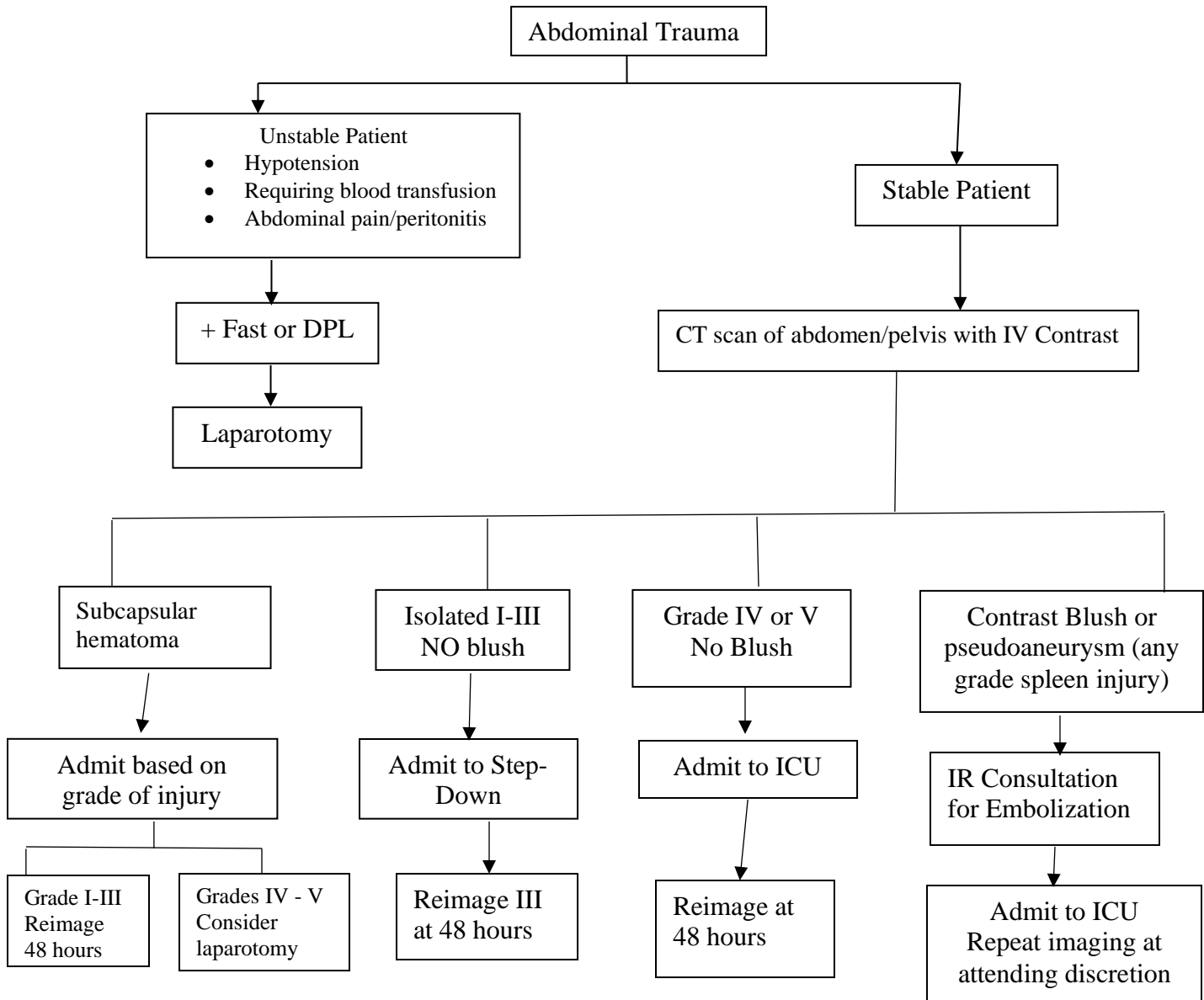


GUIDELINE FOR MANAGEMENT OF SPLEEN INJURY IN ADULTS



- Hgb decreases requiring transfusion – consider laparotomy or embolization
- Increase in subcapsular hematoma at reimaging – consider laparotomy
- Develops worsening abdominal pain/peritonitis or hemodynamic instability – laparotomy