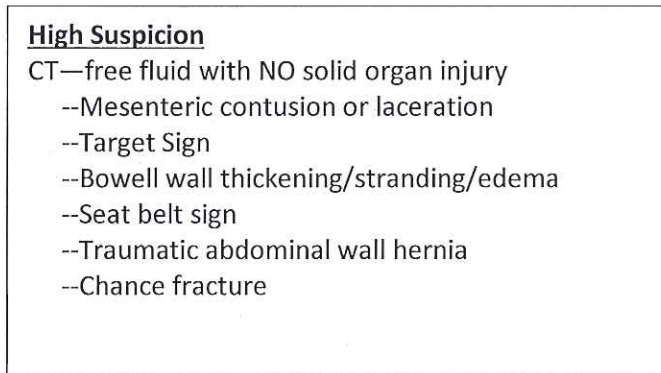



Workup of Small Bowel Injuries



Consider diagnostic laparoscopy or laparotomy
Admit for serial abdominal exams for 12-24° q 4° prefer with same clinician
Document
Consider repeat CT scan of abdomen and pelvis at 12-24° if increasing WBC, increased abdominal pain, persistent nausea, feeding tolerance, ↑ acidosis/lactate, invasive evaluation with laparoscopy or laparotomy

09/05/2018