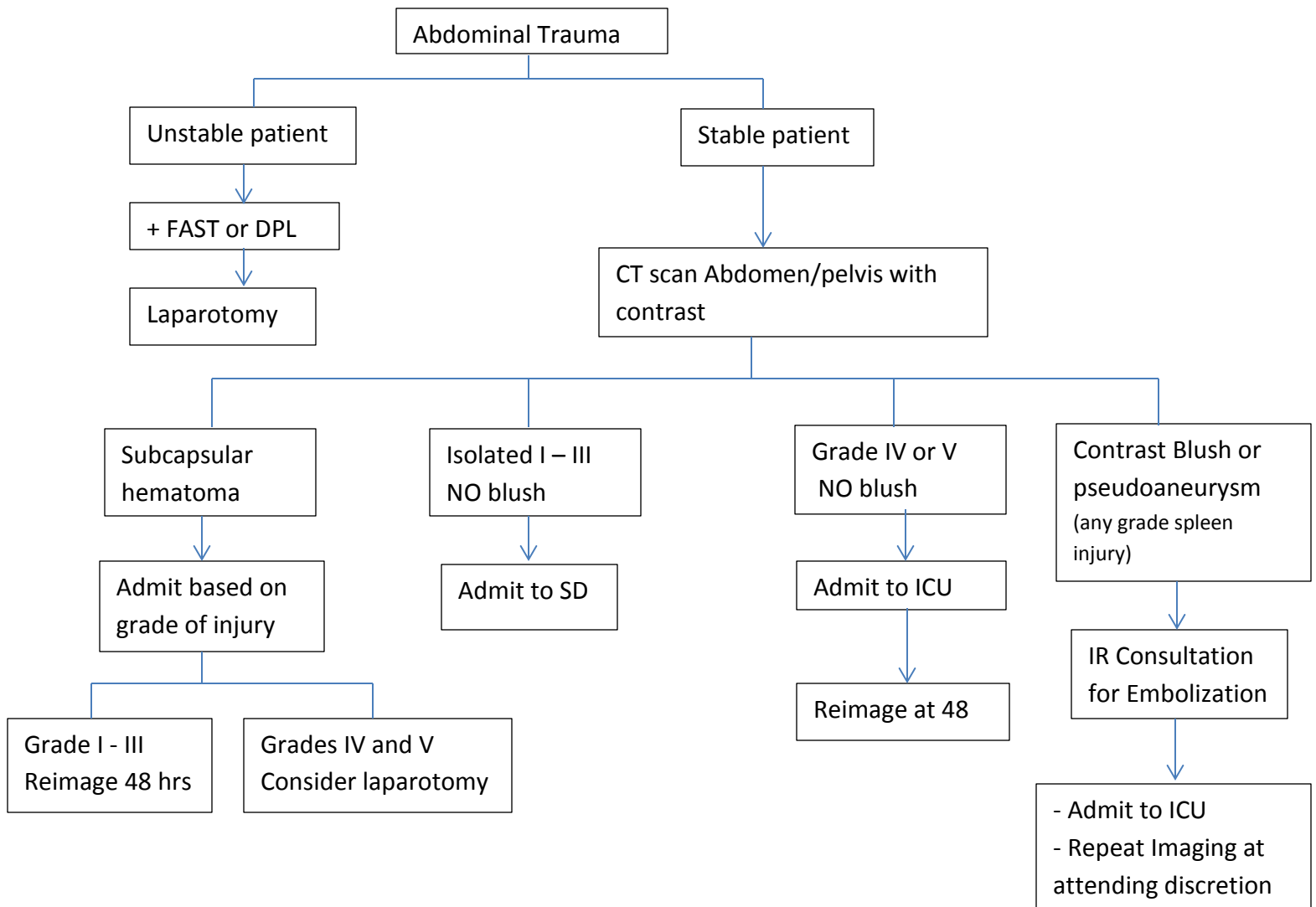


GUIDELINE FOR MANAGEMENT OF SPLEEN INJURY IN ADULTS



- Hgb decreases by 4 – consider laparotomy or embolization
- Increase in subcapsular hematoma at reimaging – consider laparotomy
- Develops hemodynamic instability – laparotomy