

Emergency Neurological Life Support: Intracranial Hypertension and Herniation

Robert D. Stevens · J. Stephen Huff · Josh Duckworth · Alexander Papangelou ·
Scott D. Weingart · Wade S. Smith

© Neurocritical Care Society 2012

Abstract Sustained intracranial hypertension and acute brain herniation are “brain codes,” signifying catastrophic neurological events that require immediate recognition and treatment to prevent irreversible injury and death. As in cardiac arrest, evidence supports the organized implementation of a stepwise management algorithm. Because there are multiple etiologies and many treatments that can potentially reverse cerebral herniation, intracranial hypertension and herniation was chosen as an Emergency Neurological Life Support (ENLS) protocol.

R. D. Stevens · J. Duckworth · A. Papangelou
Department of Anesthesiology and Critical Care Medicine,
Johns Hopkins University School of Medicine, Baltimore,
MD, USA

R. D. Stevens · J. Duckworth · A. Papangelou
Department of Neurology, Johns Hopkins University School
of Medicine, Baltimore, MD, USA

R. D. Stevens · J. Duckworth
Department of Neurosurgery, Johns Hopkins University School
of Medicine, Baltimore, MD, USA

R. D. Stevens · J. Duckworth
Department of Radiology, Johns Hopkins University School
of Medicine, Baltimore, MD, USA

J. S. Huff (✉)
Department of Emergency Medicine and Neurology, University
of Virginia School of Medicine, Charlottesville, VA, USA
e-mail: jshuff505@me.com

S. D. Weingart
ENLS Course Co-Chair, Division of ED Critical Care,
Mount Sinai School of Medicine, New York, NY, USA

W. S. Smith
ENLS Course Co-Chair, Department of Neurology,
University of California, San Francisco, CA, USA
e-mail: smithw@neurology.ucsf.edu

Keywords ICP · Cerebral perfusion pressure ·
Mass effect · Ventriculostomy · Osmotherapy ·
hypertonic saline · Protocol

Introduction

The ENLS-suggested algorithm for the initial management of intracranial hypertension or herniation is shown in Fig. 1.

The sum of intracranial contents—brain, blood, and cerebrospinal fluid (CSF)—represents a fixed volume determined by the invariant constraints of the cranial vault [1, 2]. Relative volumes of these contents will change to accommodate a space-occupying mass; however, this compensation is lost once a critical volume change has occurred, as demonstrated by the inflection point of the pressure–volume relationship (Fig. 2). Intracranial hypertension and cerebral herniation are “brain codes”—life-threatening neurological emergencies signifying that that intracranial compliance adaptive mechanisms have been overwhelmed.

Although frequently linked, elevations of intracranial pressure (ICP) and brain herniation can occur independently. Intracranial hypertension is defined as a sustained (>5 min) elevation of ICP of >20 mmHg [3]. Detection requires invasive monitoring, but certain clinical and physiological signs may suggest elevated ICP prior to instrumentation. Herniation syndromes result from intracranial compartmental pressure gradients leading to parenchymal tissue shifts that compress or displace the brainstem, cranial nerves, or cerebral vasculature. Ischemia or infarction from vascular compression may cause edema and further deterioration in compliance.

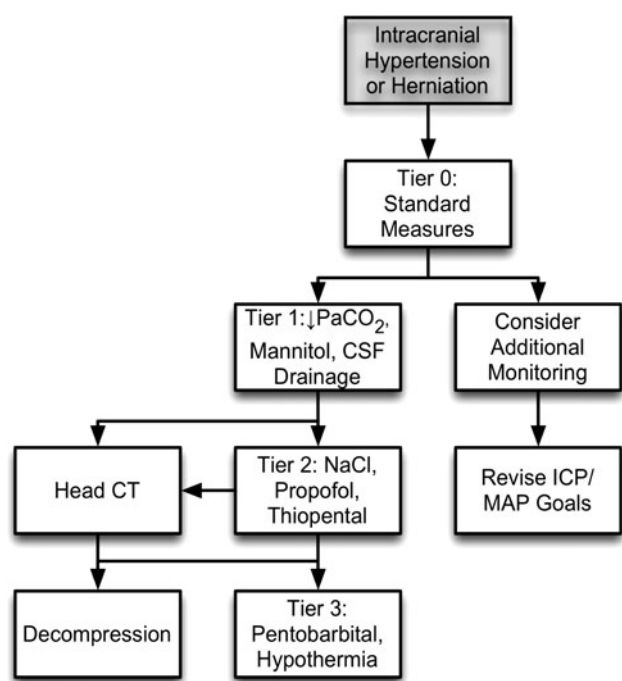


Fig. 1 ENLS intracranial hypertension or herniation protocol

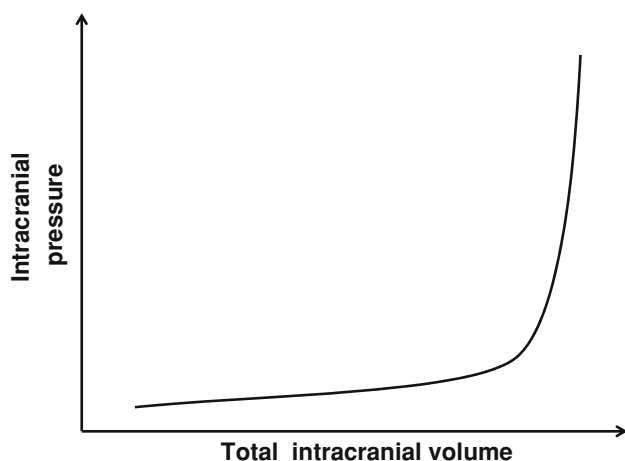


Fig. 2 Intracranial compliance is biphasic

The etiologies of brain code are classified anatomically as extra-axial or intraparenchymal processes which can be focal or diffuse (Table 1). In the emergent setting of a brain code, resuscitative measures are pursued even if the etiological mechanism has not been fully characterized.

Presentation

Clinically, increased ICP may be signaled by the presence of headache, hypertension, bradycardia, and irregular respirations or apnea (Cushing's triad), though the concurrence of three signs is uncommon [4]. Common sites for

Table 1 Etiologies of brain code

Extra-axial process
Epidural hemorrhage
Subdural hemorrhage
Subdural empyema
Extra-axial brain tumor
Pneumocephalus
Focal brain process
Brain tumor (primary, metastatic)
Ischemic stroke
Primary intracerebral hemorrhage
Brain abscess
Traumatic brain injury
Hydrocephalus
Diffuse brain process
Traumatic brain injury
Aneurysmal subarachnoid hemorrhage
Infectious meningitides and encephalitides
Non-infectious neuroinflammatory disorders
Hepatic encephalopathy
Toxic-metabolic encephalopathies

herniation are the cingulum (subfalcine herniation), medial temporal lobe (uncal herniation), and inferior cerebellum (tonsillar herniation).

The cardinal signs of transtentorial (uncal) herniation are an acute loss of consciousness associated with ipsilateral pupillary dilation and contralateral hemiparesis, resulting respectively from compression or displacement of ascending arousal pathways, oculomotor nerve (III), and corticospinal tract [5, 6]. Transtentorial herniation may cause ipsilateral cerebral infarction because of occlusion of the posterior cerebral artery. In a subset of patients, herniation-associated shift of the midbrain compresses the contralateral anterior cerebral peduncle (crus cerebri) against the tentorium, resulting in hemiparesis that is ipsilateral to the lesion (Kernohan's false localizing sign) [7].

Neuroimaging

In the emergent setting of a brain code, a cranial-computed tomography (CT) scan should be obtained without delay to identify a process that may require surgical intervention. Initial resuscitative measures and stabilization, including airway interventions and provision of circulatory and ventilatory support, must occur prior to transport to the radiology suite. Cranial CT is preferred over magnetic resonance imaging (MRI) due to availability and speed of imaging. In the majority of cases, CT will identify the underlying process (see Table 1), though MRI may

subsequently be needed for characterization. MRI should only be sought if the risk of an additional brain code has been addressed by medical and/or surgical intervention.

ICP Monitoring

ICP monitors are invasive and are of several different types, including intraventricular catheters as well as intraparenchymal, subdural, and epidural devices. The decision to proceed with ICP monitoring is determined by the underlying process and the likelihood of its progression. In traumatic brain injury (TBI), neurosurgical guidelines recommended placement of an ICP monitor in patients with severe TBI who are comatose after resuscitation (Glasgow Coma Scale, or GCS, of 3–8) and have either (1) abnormalities on cranial CT scan *or* (2) meet at least two of the following three criteria: age older than 40 years, systolic blood pressure <90 mmHg, or abnormal posturing [8].

Cerebral perfusion pressure (CPP), used as a surrogate for global cerebral blood flow (CBF), is approximated by the equation:

$$\text{CPP} = \text{mean arterial pressure (MAP)} - \text{ICP}$$

In patients with TBI, available data support maintaining CPP >50–60 mmHg to prevent cerebral ischemia [3]. Aggressive efforts to maintain CPP >60 mmHg may elevate the risk of systemic complications, including acute respiratory distress syndrome [9]. Indications for ICP monitoring and CPP targets for patients with non-traumatic intracranial hypertension have not been adequately studied.

Tier Zero

Brain code resuscitation begins with an assessment for adequate circulation, airway patency, and ventilation. The head of the bed should be elevated to 30 degrees or higher to facilitate cerebral venous drainage [10, 11]. Stimuli, such as tracheal suctioning that may elevate ICP, should be minimized. If hyperthermia is present, measures should be taken to lower body and brain temperature. Only iso- or hyperosmotic fluids should be used as intravenous solutions. If hyponatremia is present, steps should be initiated for correction. High-dose corticosteroid therapy is initiated for vasogenic edema resulting from brain tumors, abscesses, or non-infectious neuroinflammatory conditions [12, 13]. If the brain has not yet been imaged, a non-contrast head CT scan should be performed when the patient can be safely transported.

Tier One

If acute obstructive hydrocephalus is present as determined by neuroimaging, an external ventricular drainage (EVD) system should be placed emergently. If a ventricular shunt or an EVD system is in place, drain 5–10 ml of cerebrospinal fluid [14]. Mannitol is administered as 0.5–1 g/kg intravenous (IV) bolus and may be repeated every 4–6 h if serum osmolality is monitored [15]. No therapeutic benefit is appreciable with osmolality >320 mOsm/kg. As a temporizing measure, a brief course (<2 h) of hyperventilation to a PaCO₂ of 30–35 mmHg may be considered [16, 17]. If ICP is not controlled, and/or clinical signs of herniation do not resolve with Tier One interventions, review decompressive surgical options [18, 19]. If surgery is not appropriate or not undertaken, move to Tier Two. If ICP is controlled with Tier One interventions, consider repeating the head CT scan to rule out new processes.

Head CT

After Tier One or Tier Two (the following), if brain imaging has not yet been performed, a head CT scan should be performed to determine the cause of herniation or intracranial hypertension, for the reasons explained in the [Neuroimaging](#) section earlier.

Tier Two

If Tier One interventions have failed to control ICP, Tier Two should be engaged. Brain edema and ICP are treatable with hypertonic saline in concentrations ranging from 2 to 23.4 %. Concentrations >3 % are preferably administered via a central venous catheter (when using concentrations lower than this, peripheral lines may be used, but the infusion should be in a large vessel, and the IV site should be carefully monitored for infiltration). However, because two prehospital trials using 7.5 and 3 % saline solutions via peripheral lines had no negative local effects, these treatments should not be withheld simply because central access is not yet available [20, 21]. Bolus 23.4 % saline has been associated with ICP reduction and reversal of tentorial herniation [22]. When infusing hypertonic saline, a target serum sodium concentration should be identified and serum sodium level checked every 4–6 h. The therapeutic benefit of achieving serum sodium levels >160 mmol/l is not known.

Propofol reduces CMRO₂ and CBF volume and, consequently, ICP [23]. It is administered as a bolus of 1–3 mg/kg and may be continued as an infusion (titrate to maximum 200 µg/kg/min). Propofol is associated with

circulatory depression, which should be corrected with IV fluids and/or vasopressors/inotropes to maintain CPP goal. A subset of patients receiving infusions of propofol develop a syndrome of metabolic acidosis, cardiac dysfunction, rhabdomyolysis, and hypertriglyceridemia, often with a fatal outcome [24, 25]. If ICP is not responsive to Tier Two interventions, rescue decompressive surgery should be considered. If the patient is ineligible for surgery, Tier Three should be engaged.

Decompression

Surgery is considered for brain code patients who have failed medical management. Decompressive surgical interventions for the management of brain code include (a) placement of a ventricular drain, (b) evacuation of extra-axial lesion (e.g., epidural hematoma), (c) resection of intracerebral lesion (e.g., lobar hemorrhage), (d) removal brain parenchyma (e.g., cerebellar mass), and (d) uni- or bilateral craniectomies.

Selected patients with rapid neurological deterioration from focal space-occupying lesions may benefit from surgical decompression. This includes patients with brain tumors, brain abscesses, and parenchymal hemorrhages, particularly when the hemorrhages are lobar [26] or cerebellar [27, 28] in location. Decompressive craniectomy may also be considered in patients with diffuse brain swelling associated with traumatic brain injury [29–32]; stroke with massive brain edema, the process in which hemicraniectomy has been most extensively studied [33, 34]; meningoen- cephalitis; or non-infectious neuroinflammatory conditions (e.g., acute demyelinating encephalomyelitis).

Tier Three

Tier Three measures represent the most aggressive level of management and carry the highest risk of adverse effects. Rigorous randomized prospective studies are lacking, and recommendations are driven by consensus. This tier includes administration of pentobarbital (bolus 10 mg/kg over 30 min, then 5 mg/kg/h \times 3 h; maintenance infusion of 1–4 mg/kg/h titrated to ICP goal). The electroencephalogram (EEG) should be continuously monitored and pentobarbital titrated either to ICP or to EEG burst suppression of 5–20 s. The pentobarbital infusion is continued for 24–96 h while the underlying processes driving ICP are treated [35–37]. Pentobarbital is associated with respiratory depression, circulatory instability, immune suppression, and paralytic ileus; neurological examination is limited to

an assessment of pupillary reactivity, and drug clearance may take several days after discontinuation of infusion.

Moderate hypothermia (target core temperature 32–34 °C) is induced with external cooling devices or with IV infusion of cooled fluids [38–43]. Treatment may be associated with shivering, cardiac arrhythmias, sepsis, coagulopathy, and electrolyte disturbances.

Hyperventilation to achieve moderate hypocapnia (PaCO₂ 25–35 mmHg) may be considered in selected patients who have failed other management. Aggressive hyperventilation should be accomplished in conjunction with a cerebral oxygenation monitor (e.g., jugular venous oximetry, brain tissue oxygen probe), to minimize the risk of cerebral ischemia. Prolonging hyperventilation for > 6 h is unlikely to be beneficial and may cause ischemic brain injury [17].

Consider Additional Monitoring

Patients who have had or are at risk for a brain code may benefit from additional neuromonitoring, including jugular venous oximetry, brain tissue oxygenation, and cerebral microdialysis. Treatment based on ICP and CPP alone overlooks significant information on the physiologic and metabolic state of the injured brain. Furthermore, assumptions regarding CPP may not hold if CBF auto-regulation is impaired. Complementary neuromonitoring techniques should be considered to optimize medical management in selected patients with severe brain injury.

Studies using brain tissue oxygen sensors indicate that significant parenchymal hypoxia may occur even when ICP and CPP are normal [44, 45]. Cerebral microdialysis measures brain interstitial lactate, pyruvate, glucose, and glutamate—indicators of cerebral metabolic distress whose levels may be altered independently of ICP and CPP [46]. Dynamic indices of cerebral auto-regulation express the correlation between a systemic hemodynamic parameter (arterial blood pressure or CPP) and an intracranial physiological parameter such as ICP (PRx), transcranial Doppler-derived CBF velocity (Mx), or brain tissue PO₂ (Orx). High degrees of correlation suggest a failure of auto-regulation and an increased risk of injury because of hypo or hyperperfusion [47, 48].

Revise ICP/MAP Goals

Depending on the specific circumstances and the invasive or non-invasive monitoring that is available, the standard goals of MAP and ICP should be reconsidered and customized to the patient. For example, a patient who is

neurologically intact, but has an ICP in excess of 20 mmHg or a CPP < 60 mmHg, may not require intervention.

References

1. Monro A. Observations on the structure and functions of the nervous system. Edinburgh: Printed for, and sold by, W. Creech; 1783.
2. Kellie G. Appearances observed in the dissection of two individuals; death from cold and congestion of the brain. *Trans Med Chir Soc Edinburgh*. 1824;1:84.
3. Brain Trauma Foundation, American Association of Neurological Surgeons, Congress of Neurological Surgeons, et al. Guidelines for the management of severe traumatic brain injury. VIII. Intracranial pressure thresholds. *J Neurotrauma*. 2007;24 Suppl 1: S55–8.
4. Cushing H. Concerning a definite regulatory mechanism of the vasomotor centre which controls blood pressure during cerebral compression. *Bull Johns Hopkins Hosp*. 1901;126:289–92.
5. Meyer A. Herniation of the brain. *Arch Neurol Psychiatry*. 1920; 4:387–400.
6. Ropper AH. Lateral displacement of the brain and level of consciousness in patients with an acute hemispherical mass. *N Engl J Med*. 1986;314:953–8.
7. Kernohan JW, Woltman HW. Incisura of the crus due to contralateral brain tumour. *Arch Neurol Psychiatry*. 1929;21:274–87.
8. Brain Trauma Foundation, American Association of Neurological Surgeons, Congress of Neurological Surgeons, et al. Guidelines for the management of severe traumatic brain injury. VI. Indications for intracranial pressure monitoring. *J Neurotrauma*. 2007;24 Suppl 1:S37–44.
9. Contant CF, Valadka AB, Gopinath SP, Hannay HJ, Robertson CS. Adult respiratory distress syndrome: a complication of induced hypertension after severe head injury. *J Neurosurg*. 2001; 95:560–8.
10. Feldman Z, Kanter MJ, Robertson CS, et al. Effect of head elevation on intracranial pressure, cerebral perfusion pressure, and cerebral blood flow in head-injured patients. *J Neurosurg*. 1992; 76:207–11.
11. Ng I, Lim J, Wong HB. Effects of head posture on cerebral hemodynamics: its influences on intracranial pressure, cerebral perfusion pressure, and cerebral oxygenation. *Neurosurgery*. 2004;54:593–7: Discussion: 8.
12. Galicich JH, French LA, Melby JC. Use of dexamethasone in treatment of cerebral edema associated with brain tumors. *J Lancet*. 1961;81:46–53.
13. Quartey GR, Johnston JA, Rozdilsky B. Decadron in the treatment of cerebral abscess. An experimental study. *J Neurosurg*. 1976;45:301–10.
14. Kerr EM, Marion D, Sereika MS, et al. The effect of cerebrospinal fluid drainage on cerebral perfusion in traumatic brain injured adults. *J Neurosurg Anesthesiol*. 2000;12:324–33.
15. Francony G, Fauvage B, Falcon D, et al. Equimolar doses of mannitol and hypertonic saline in the treatment of increased intracranial pressure. *Crit Care Med*. 2008;36:795–800.
16. Coles JP, Minhas PS, Fryer TD, et al. Effect of hyperventilation on cerebral blood flow in traumatic head injury: clinical relevance and monitoring correlates. *Crit Care Med*. 2002;30:1950–9.
17. Muizelaar JP, Marmarou A, Ward JD, et al. Adverse effects of prolonged hyperventilation in patients with severe head injury: a randomized clinical trial. *J Neurosurg*. 1991;75:731–9.
18. Eberle BM, Schnuriger B, Inaba K, Gruen JP, Demetriades D, Belzberg H. Decompressive craniectomy: surgical control of traumatic intracranial hypertension may improve outcome. *Injury*. 2010;41:894–8.
19. Johnson RD, Maartens NF, Teddy PJ. Decompressive craniectomy for malignant middle cerebral artery infarction: evidence and controversies. *J Clin Neurosci*. 2011;18:1018–22.
20. Bulger EM, May S, Brasel KJ, et al. Out-of-hospital hypertonic resuscitation following severe traumatic brain injury: a randomized controlled trial. *JAMA*. 2012;304:1455–64.
21. Dubick MA, Wade CE. A review of the efficacy and safety of 7.5 % NaCl/6 % dextran 70 in experimental animals and in humans. *J Trauma*. 1994;36:323–30.
22. Koenig MA, Bryan M, Lewin JL 3rd, Mirski MA, Geocadin RG, Stevens RD. Reversal of transtentorial herniation with hypertonic saline. *Neurology*. 2008;70:1023–9.
23. Kelly DF, Goodale DB, Williams J, et al. Propofol in the treatment of moderate and severe head injury: a randomized, prospective double-blinded pilot trial. *J Neurosurg*. 1999;90: 1042–52.
24. Roberts RJ, Barletta JF, Fong JJ, et al. Incidence of propofol-related infusion syndrome in critically ill adults: a prospective, multicenter study. *Crit Care*. 2009;13:R169.
25. Fong JJ, Sylvia L, Ruthazer R, Schumaker G, Kcomt M, Devlin JW. Predictors of mortality in patients with suspected propofol infusion syndrome. *Crit Care Med*. 2008;36:2281–7.
26. Mendelow AD, Gregson BA, Fernandes HM, et al. Early surgery versus initial conservative treatment in patients with spontaneous supratentorial intracerebral haematomas in the International Surgical Trial in Intracerebral Haemorrhage (STICH): a randomised trial. *Lancet*. 2005;365:387–97.
27. Pfefferkorn T, Eppinger U, Linn J, et al. Long-term outcome after suboccipital decompressive craniectomy for malignant cerebellar infarction. *Stroke*. 2009;40:3045–50.
28. Raco A, Caroli E, Isidori A, Salvati M. Management of acute cerebellar infarction: one institution's experience. *Neurosurgery*. 2003;53:1061–5: Discussion: 5–6.
29. Jiang JY, Xu W, Li WP, et al. Efficacy of standard trauma craniectomy for refractory intracranial hypertension with severe traumatic brain injury: a multicenter, prospective, randomized controlled study. *J Neurotrauma*. 2005;22:623–8.
30. Olivecrona M, Rodling-Wahlstrom M, Naredi S, Koskinen LO. Effective ICP reduction by decompressive craniectomy in patients with severe traumatic brain injury treated by an ICP-targeted therapy. *J Neurotrauma*. 2007;24:927–35.
31. Taylor A, Butt W, Rosenfeld J, et al. A randomized trial of very early decompressive craniectomy in children with traumatic brain injury and sustained intracranial hypertension. *Childs Nerv Syst*. 2001;17:154–62.
32. Cooper DJ, Rosenfeld JV, Murray L, et al. Decompressive craniectomy in diffuse traumatic brain injury. *N Engl J Med*. 2011;364:1493–502.
33. Hofmeijer J, Kappelle LJ, Algra A, et al. Surgical decompression for space-occupying cerebral infarction (the Hemicraniectomy After Middle Cerebral Artery infarction with Life-threatening Edema Trial [HAMLET]): a multicentre, open, randomised trial. *Lancet Neurol*. 2009;8:326–33.
34. Vahedi K, Hofmeijer J, Juettler E, et al. Early decompressive surgery in malignant infarction of the middle cerebral artery: a pooled analysis of three randomised controlled trials. *Lancet Neurol*. 2007;6:215–22.
35. Brain Trauma Foundation. The use of barbiturates in the control of intracranial hypertension. *J Neurotrauma*. 1996;13:711–4.
36. Eisenberg HM, Frankowski RF, Contant CF, Marshall LF, Walker MD. High-dose barbiturate control of elevated intracranial pressure in patients with severe head injury. *J Neurosurg*. 1988;69:15–23.

37. Perez-Barcena J, Llompарт-Pou JA, Homar J, et al. Pentobarbital versus thiopental in the treatment of refractory intracranial hypertension in patients with traumatic brain injury: a randomized controlled trial. *Crit Care*. 2008;12:R112.
38. Jiang J, Yu M, Zhu C. Effect of long-term mild hypothermia therapy in patients with severe traumatic brain injury: 1-year follow-up review of 87 cases. *J Neurosurg*. 2000;93:546–9.
39. Liu WG, Qiu WS, Zhang Y, Wang WM, Lu F, Yang XF. Effects of selective brain cooling in patients with severe traumatic brain injury: a preliminary study. *J Int Med Res*. 2006;34:58–64.
40. Marion DW, Obrist WD, Carlier PM, Penrod LE, Darby JM. The use of moderate therapeutic hypothermia for patients with severe head injuries: a preliminary report. *J Neurosurg*. 1993;79:354–62.
41. Marion DW, Penrod LE, Kelsey SF, et al. Treatment of traumatic brain injury with moderate hypothermia. *N Engl J Med*. 1997;336:540–6.
42. Qiu W, Zhang Y, Sheng H, et al. Effects of therapeutic mild hypothermia on patients with severe traumatic brain injury after craniotomy. *J Crit Care*. 2007;22:229–35.
43. Shiozaki T, Sugimoto H, Taneda M, et al. Effect of mild hypothermia on uncontrollable intracranial hypertension after severe head injury. *J Neurosurg*. 1993;79:363–8.
44. Chang JJ, Youn TS, Benson D, et al. Physiologic and functional outcome correlates of brain tissue hypoxia in traumatic brain injury. *Crit Care Med*. 2009;37:283–90.
45. Longhi L, Pagan F, Valeriani V, et al. Monitoring brain tissue oxygen tension in brain-injured patients reveals hypoxic episodes in normal-appearing and in peri-focal tissue. *Intensive Care Med*. 2007;33:2136–42.
46. Chen HI, Stiefel MF, Oddo M, et al. Detection of cerebral compromise with multimodality monitoring in patients with subarachnoid hemorrhage. *Neurosurgery*. 2011;69:53–63: Discussion.
47. Schmidt B, Czosnyka M, Raabe A, et al. Adaptive noninvasive assessment of intracranial pressure and cerebral autoregulation. *Stroke*. 2003;34:84–9.
48. Brady K, Joshi B, Zweifel C, et al. Real-time continuous monitoring of cerebral blood flow autoregulation using near-infrared spectroscopy in patients undergoing cardiopulmonary bypass. *Stroke*. 2010;41:1951–6.